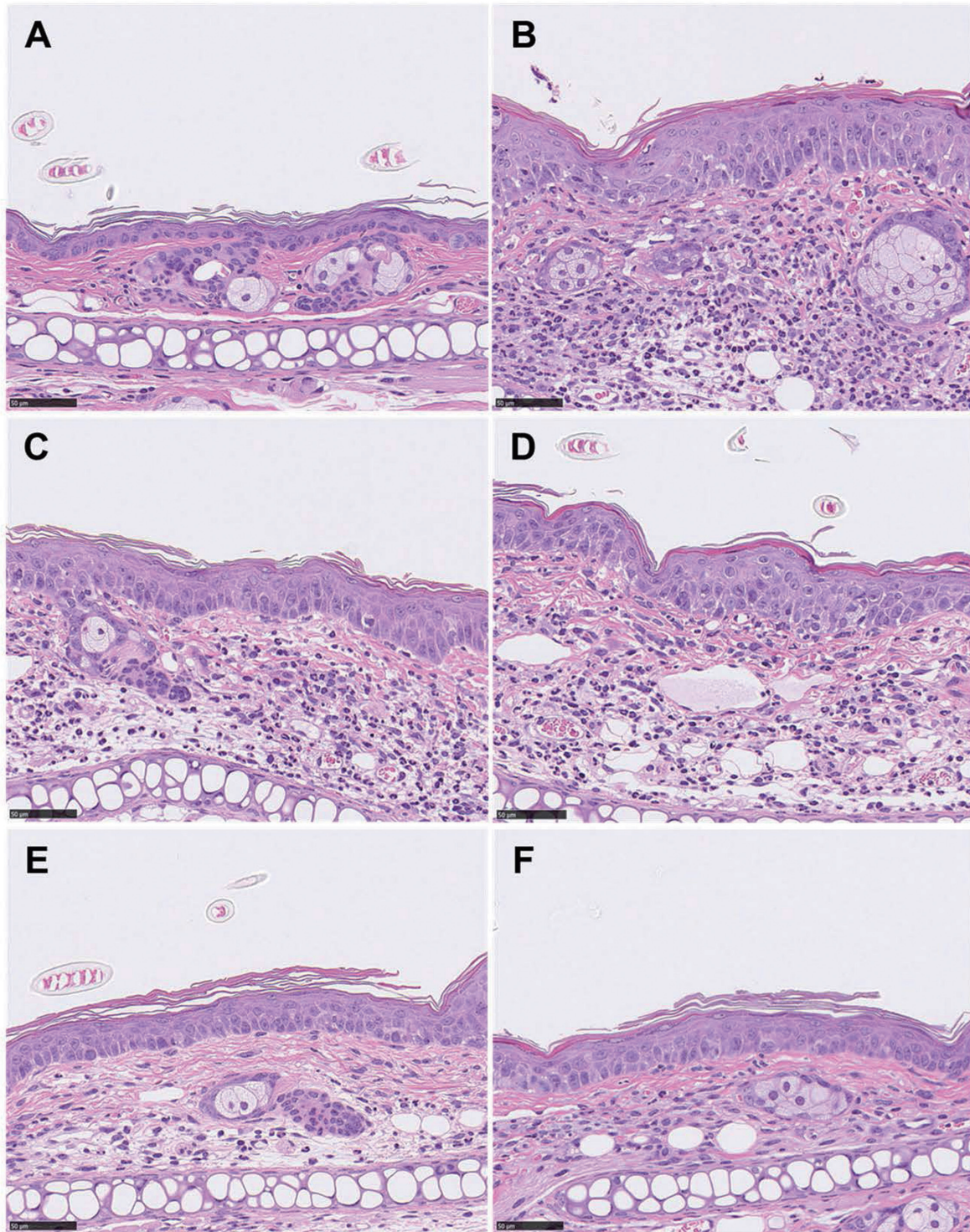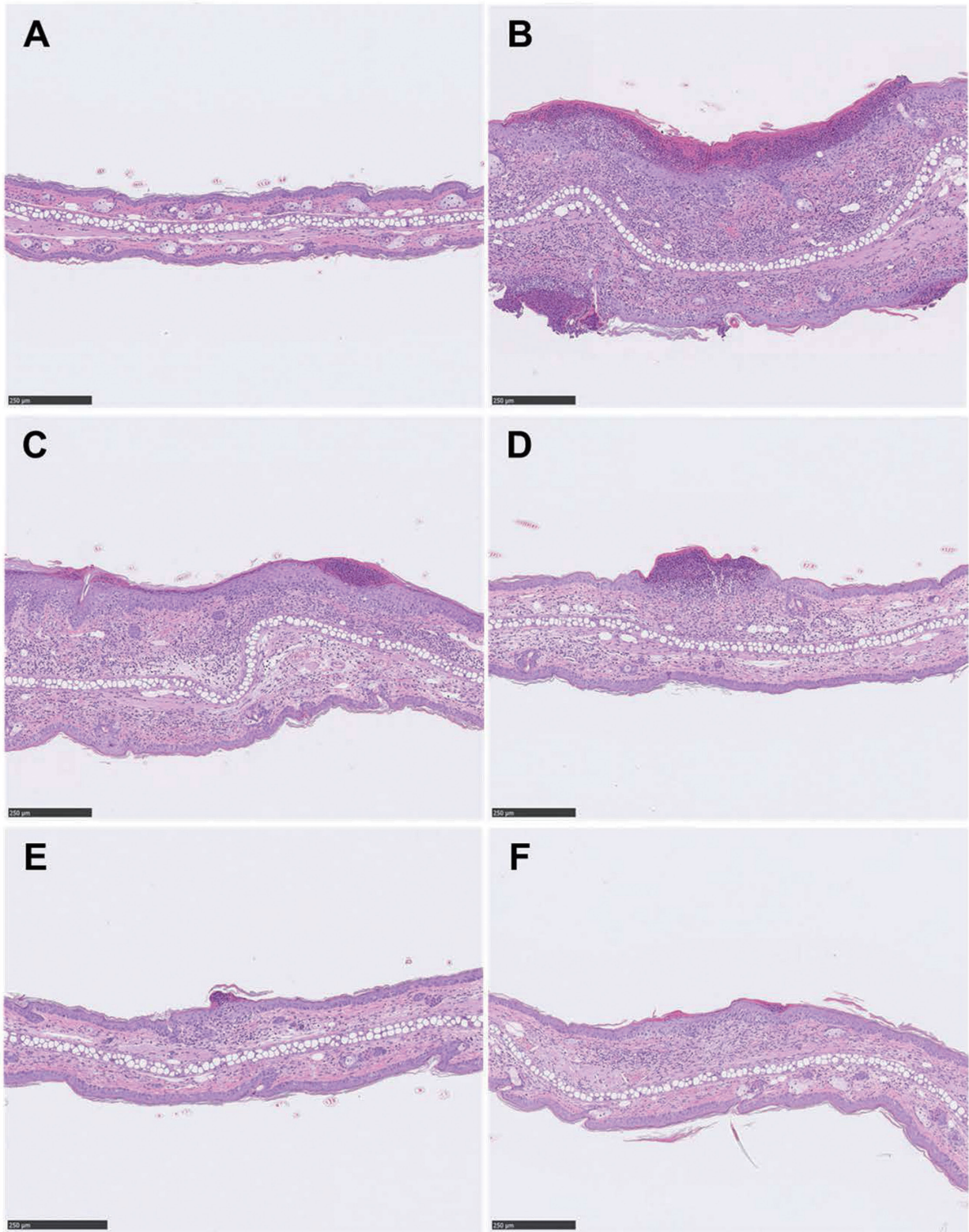


**Supplementary Fig. S1.** Effect of tapinarof on acanthosis of the ear skin in DNFB-induced dermatitis in mice. Histological analysis of the ear skin samples stained with HE was performed. Representative photomicrographs of sham, normal ear skin (A); vehicle, moderate acanthosis (B); 0.01% tapinarof, slight (C); 0.1% tapinarof, slight (D); 1% tapinarof, very slight (E), and 1% FK506, very slight acanthosis (F) are shown. Bar = 50  $\mu$ m.



**Supplementary Fig. S2.** Effect of tapinarof on crust of the ear skin in DNFB-induced dermatitis in mice. Histological analysis of the ear skin samples stained with HE was performed. Representative photomicrographs of sham, normal ear skin (A); vehicle, moderate crust (B); 0.01% tapinarof, slight (C); 0.1% tapinarof, slight (D); 1% tapinarof, very slight (E), and 1% FK506, very slight crust (F) are shown. Bar = 250  $\mu\text{m}$ .